

# COMPUTED TOMOGRAPHY STUDY: SIMULTANEOUS FAT AND MUSCLE EFFECT

COMPUTED TOMOGRAPHY (CT) BASED EVIDENCE OF SIMULTANEOUS CHANGES IN HUMAN ADIPOSE AND MUSCLE TISSUES FOLLOWING A HIGH INTENSITY FOCUSED ELELCTRO-MAGNETIC FIELD (HIFEM®) APPLICATION: A NEW METHOD FOR NON-INVASIVE BODY SCULPTING.

David E. Kent M.D.<sup>1</sup>, Carolyn I. Jacob M.D.<sup>2</sup>

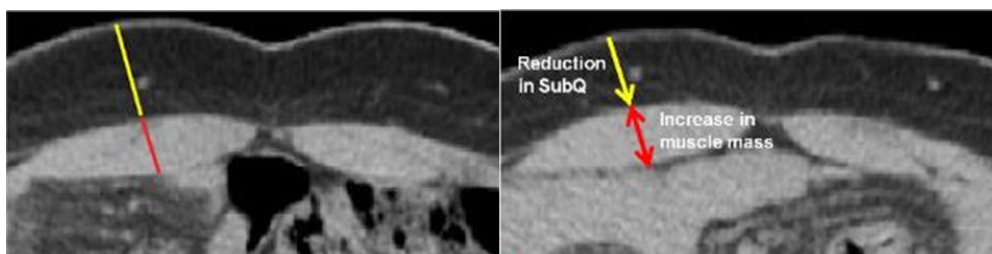
1. Dermatologic Surgery Specialists, Macon GA, USA; 2. Chicago Cosmetic Surgery and Dermatology, Chicago IL, USA

Presented at the Annual Meeting of the American Society for Laser Medicine and Surgery, 2018 Dallas, TX.

---

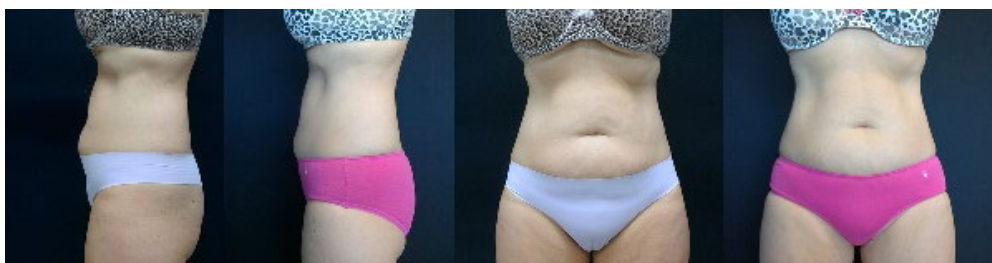## HIGHLIGHTS

- 16 patients received 5-8 treatments to evaluate effects of an extended protocol. Subject were evaluated 1 month post-treatments.
- Abdominal **fat thickness** was **reduced** on average by **19.2 %** or 3.4 mm.
- Simultaneously a **15.8 % increase in abdominal muscle thickness** was observed, coupled with a 10.8 % reduction in diastasis recti.
- **Waist circumference decreased** on average by **1.2 inch** (after 4th Tx) and 1.6 inch (after the last Tx).
- Data suggest **4 treatments as the ideal protocol**.



BASELINE

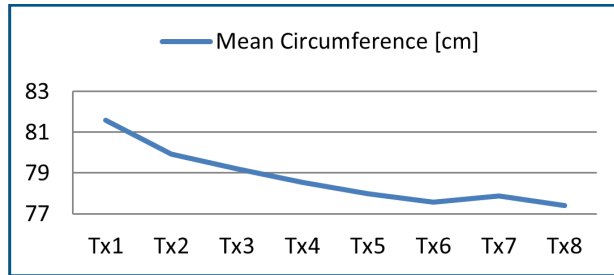
1 MONTH FU



# RESULTS

## UMBILICAL CIRCUMFERENCE

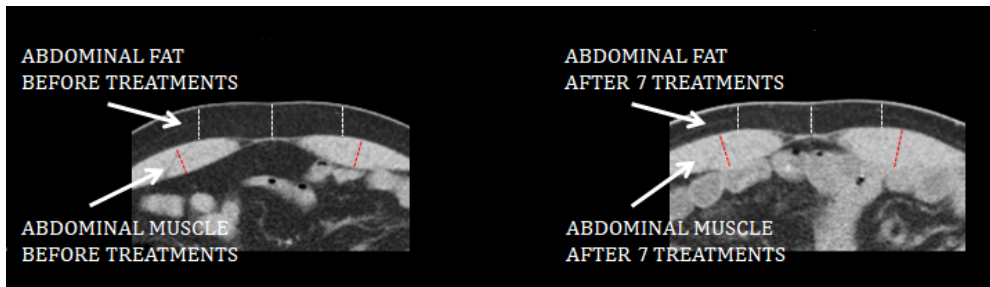
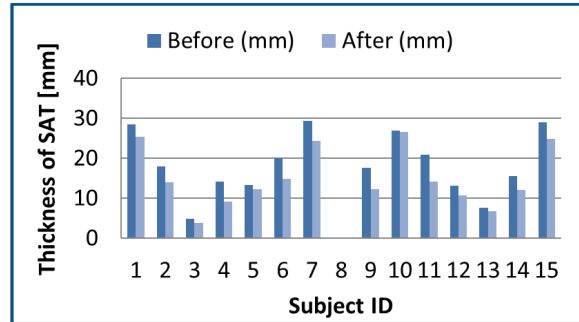
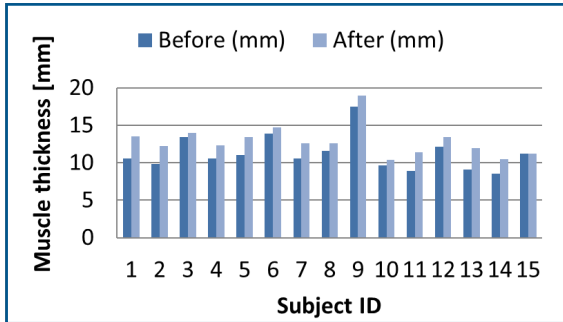
- The average circumference decreased by 3.04 cm and 4.17 cm after 4th and last (5th to 8th) treatment, respectively ( $p < 0.003$ )



## CT MEASUREMENTS

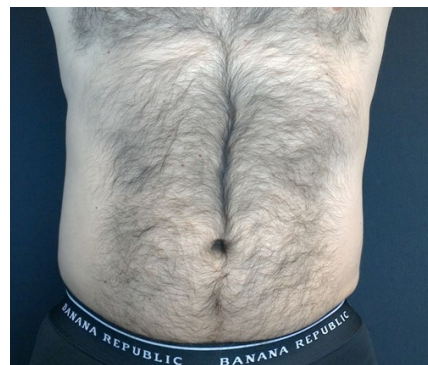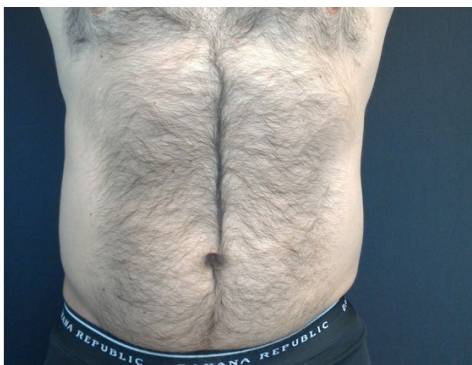CT calculated thickness of rectus abdominis at baseline and 1 month post treatments.

Subcutaneous fat thickness at baseline and 1-month post treatments. Patient ID8 fat measurements could not be objectively made due to close-to-zero baseline fat thickness.



BASELINE

1 MONTH FU



CT scans of patient ID9 at baseline (left) and 1-month post treatments (right). The scan shows reduction of subcutaneous fat (-30.3%) and thickening of rectus abdominis muscle (+8.4%).